

**Non-surgical management of a large periapical lesion: case report.****Saurabh Ramtekkar, Manjusha Warhadpande, Darshan Dakshindas**

Department of Conservative Dentistry and Endodontics, Government Dental College and Hospital, Nagpur, India.

**Abstract**

This case report describes non-surgical management of a large periapical lesion in the maxillary anterior region of a 19-year-old male with chief complaint of periodic swelling and pus discharge from the maxillary anterior region. He had history of trauma in this area. Both maxillary right central incisor and lateral incisor were non responsive to electric and thermal pulp tests and central incisor was discoloured. Root canals of both incisors were properly cleaned and disinfected with calcium hydroxide medicament. After resolution of signs and symptoms, obturation was done. Clinical and radiographic assessment at 6 months, 12 months and 18 months reveal progressing bone healing. This case report shows that appropriate diagnosis along with root canal treatment as a conservative non-surgical approach can lead to complete healing of large lesions without requiring invasive surgical procedures.

**Keywords:** Calcium hydroxide; Disinfection; Maxillary Incisor; Nonsurgical Endodontic Treatment; Periapical lesion.

**Introduction**

Pulpal tissue infection can occur as a result of many factors like caries or trauma which can lead to tissue necrosis. Periapical tissue resorption develops in response to microbial invasion and their by-products that infiltrate the periradicular tissues and activate the host's immune reaction.<sup>1</sup> Dynamic encounter between the microbial infective factors and host's immune response at the interface of the periodontal membrane and infected pulpal

tissue leads to development of various periapical lesions.<sup>2,3</sup>

Though such periradicular lesions are defensive in nature, they are not self-healing.<sup>4</sup> The incidence of radicular cysts in such lesions have been reported to vary between 6% to 55%. The prevalence of periapical granuloma ranges from 9.3% to 87.1%, while periapical abscess from 28.7% to 70.7%.<sup>1,5</sup> Treatment approaches in the management of such cases range from non-

surgical endodontic therapy with or without endodontic surgery to tooth extraction.

Microbial elimination through effective disinfection of the root canal system using efficient chemo mechanical preparation can lead to a successful treatment outcome.<sup>6</sup> Previous investigations have shown that large periapical lesions may be treated by nonsurgical endodontic approaches.<sup>7-9</sup> This can usually be done when the lesion has direct communication with the root canal system.<sup>10</sup>

Appropriate diagnosis, proper anatomical knowledge and effective treatment strategies are important in achieving desirable outcomes for the management of such lesions. The following case report describes nonsurgical management of a large periapical lesion involving maxillary central and lateral incisors.

### **Case Report**

A 19-year old male reported with chief complaint of periodic swelling and pus discharge in front region of upper jaw in the Department of Conservative Dentistry and Endodontics, Government Dental College and Hospital, Nagpur. He had non-significant medical history, fair oral hygiene and history of trauma to maxillary anterior region 6 years back. Extra-oral examination revealed neither facial swelling nor palpable

lymph nodes. Intra-oral examination revealed sinus tract in the gingiva between maxillary right central and lateral incisor. The central incisor discoloured and grade I mobile while the clinical crown was intact (Figure 1). The adjacent mucosa was tender on palpation.

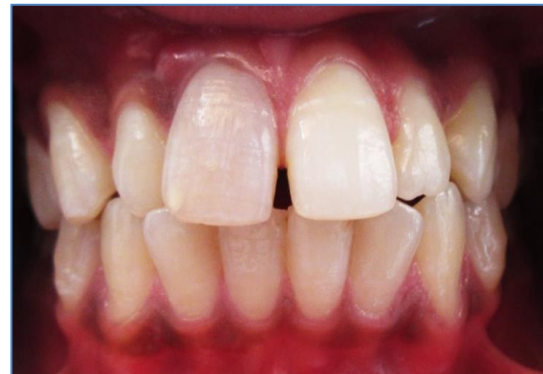

Figure 1: Discoloured right maxillary central incisor and intact clinical crowns of both central and lateral incisor.

Findings from intraoral periapical radiograph (Figure 2) and cone-beam computed tomography (CBCT) (Figure 3) showed an extensive unilocular periapical radiolucency involving the apices of maxillary right central and lateral incisors. Cold and electrical pulp tests (Gentle Pulse Analog Pulp Tester, Parkell, Edgewood, NY, USA) elicited negative response with central and lateral incisors. The clinical and radiographic findings were suggestive of periapical pathology in relation to maxillary right central and lateral incisors.

A treatment plan of nonsurgical root canal therapy was decided for the management of

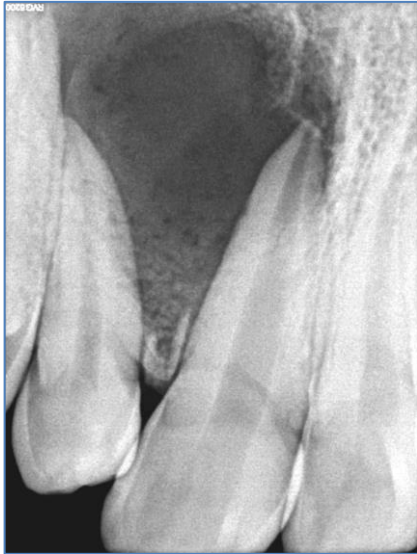

Figure 2: Intraoral periapical radiograph showing large periapical lesion involving the apices of maxillary right central and lateral incisors.

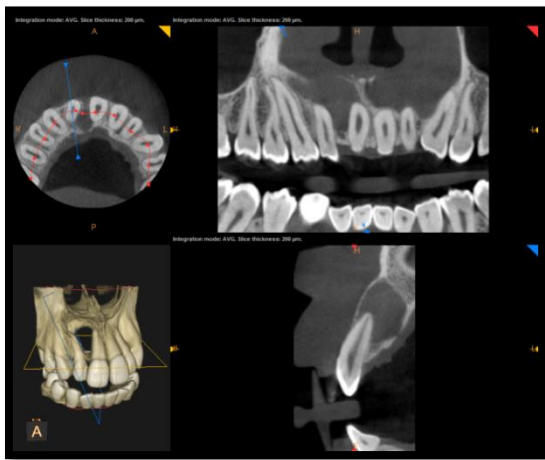


Figure 3: CBCT images showing exact location and extent of the lesion.

this case. At first appointment, local anesthesia 2% Lidocaine with 1:80,000 adrenaline (Lignox 2%-Warren-Navi Mumbai, India) was administered. Rubber dam isolation was done and endodontic

access cavity was prepared in both the incisors with a round diamond bur (Dentsply, Maillefer, Ballaigues, Switzerland).

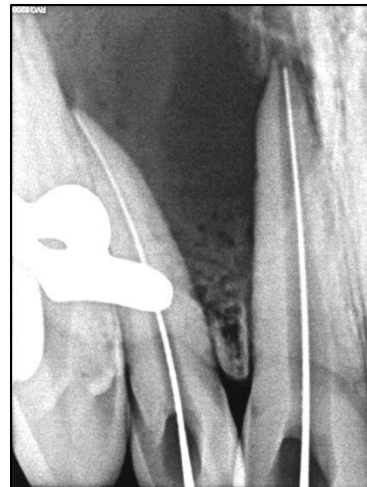

Figure 4: Radiographic working length determination.

After access cavity preparation, working length was determined radiographically (Figure 4) and biomechanical preparation was done by crown down technique with #15-80 stainless steel K-files (MANI INC, Tochigi, Japan) along with gentle irrigation with 5.25% sodium hypochlorite (Vishal Dentocare, India) and normal saline (Axaline, India). Root canals were filled with calcium hydroxide paste (RC Cal; Prime Dental products, Mumbai, India) and access cavities were sealed using temporary restorative material.

After two weeks, the root canals were again adequately irrigated and filled with calcium hydroxide paste. After four

weeks, no signs and symptoms were present. At this point thorough irrigation of the root canals was performed with 5.25% sodium hypochlorite and normal saline. The root canals were dried with absorbent paper points (Dentsply Maillefer, Switzerland) and obturated using lateral condensation of gutta-percha points (Dentsply Maillefer, Ballaigues, Switzerland) (Figure 5).

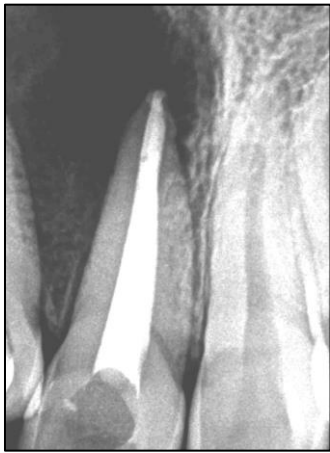


Figure 5 : Immediate Postobturation radiograph

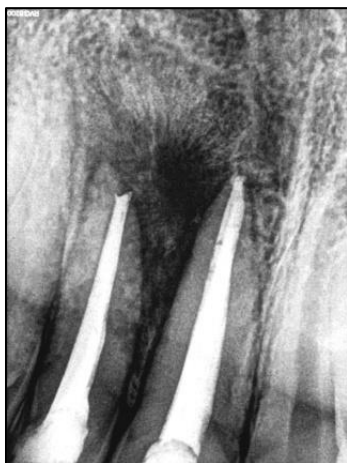


Figure 6: 6 months follow up radiograph showing periapical bone formation and decrease in the size of lesion.

Six, 12 and 18-month follow-ups indicated no sensitivity to palpation and percussion in clinical evaluations and radiographs showed evidence of bone regeneration (Figures 6 to 8).

### Discussion

Periapical lesions can be categorized as dental granulomas, radicular cysts or abscesses.<sup>11,12</sup> The occurrence of cysts in periapical lesions ranges between 6% to 55%.<sup>13</sup> Also, the occurrence of radicular cysts rises as the periapical lesions grow in size. However, some large lesions have been shown to be granulomatous in nature.<sup>14</sup> The definite diagnosis of periapical lesions can only be made through histopathological findings. Various treatment strategies of such large periapical lesions have been advocated starting from conventional nonsurgical root canal therapy with calcium hydroxide intracanal medication to various surgical procedures.<sup>15</sup> In this case, nonsurgical endodontic treatment with calcium hydroxide medication was performed.

A nonsurgical procedure should be preferred particularly in cases where lesions are in proximity to vital anatomical landmarks. Adequate cleaning, shaping, disinfection and three dimensional obturation of root canal are keys to the success of nonsurgical endodontic treatment.<sup>16</sup> In the

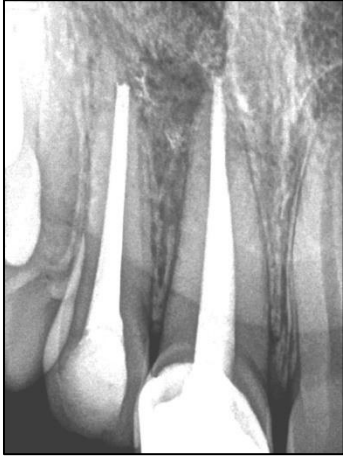

Figure 7: 12 months follow up radiograph.

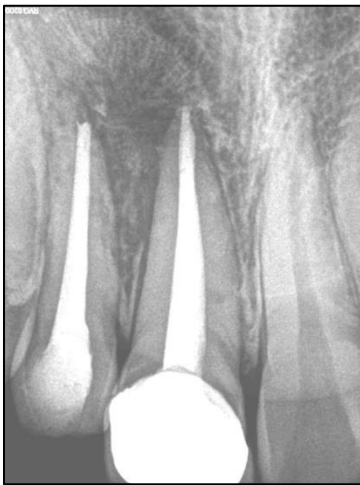

Figure 8: 18 months follow up radiograph.

present case, radiographs show a large periapical lesion with uniform radiolucency and well-defined margins involving the apices of teeth. Calcium hydroxide intracanal medicament was used because of its high alkalinity<sup>16</sup> and antibacterial effect.<sup>17,18</sup> The exact mechanism of action for this medicament is still unclear. It is recommended that calcium hydroxide paste can eliminate residual microorganisms and improve periapical

repair via handling the inflammation, stimulation of calcification, neutralizing acidic products of osteoclasts, and endotoxin neutralization.<sup>19-22</sup> Also, it has been shown that calcium hydroxide medicament enhances periapical healing, especially in young adults.<sup>23,24</sup>

In this case periapical bone healing can be observed starting from 6 months after endodontic treatment and continued over next 18 months. Radiographic evaluations demonstrated gradual decrease in the size of periapical radiolucency, progressive bone regeneration, trabecular reconstruction, and lamina dura formation.

In this case, root canal therapy, provides the highest standards of treatment with consideration of asepsis, adequate cleaning and shaping, irrigation and root canal obturation. The prognosis of large periradicular lesions is not as good as that of small ones. Strindberg and Sjogren<sup>25</sup> showed no significant differences in healing rate between lesions larger than 5 mm and those smaller than 5 mm. However, they have emphasized on the importance of a long-term follow-up for cases treated with periradicular lesions.

The lesion this case got resolved after non-surgical endodontic treatment. This may be due to rich blood supply, lymphatic drainage and abundant undifferentiated mesenchymal cells of periapical tissues because of young age of

the patient and thus overall a good potential for healing.<sup>24, 25</sup>

### **Conclusion**

Successful management of large periapical lesions can be achieved with proper non-surgical root canal therapy. In the present case, an extensive periradicular lesion was treated with calcium hydroxide intracanal medicament and root canal therapy. This confirms that large inflammatory periapical lesions can be healed satisfactorily by nonsurgical endodontic therapy.

### **Financial support and sponsorship**

Nil.

### **Conflicts of Interest**

There are no conflicts of interest.

### **References**

1. Moshari A, Vatanpour M, EsnaAshari E, Zakershahra M, Jalali Ara A. Nonsurgical Management of an Extensive Endodontic Periapical Lesion: A Case Report. *Iran Endod J* 2017;12: 116-9.
2. Bass CC. The optimum characteristics of toothbrushes for personal oral hygiene. *Dent Items Interest* 1948; 70: 696-718.
3. Bass CC. An effective method of personal oral hygiene. *J La State Med Soc* 1954; 106: 57-73.
4. Nair P. Pathobiology of primary apical periodontitis. *Pathway of the Pulp*. 9th ed. St. Louis: CV Mosby. 2006: 541-2.
5. Kimmelman BB. Teaching two tooth brushing techniques: Observations and comparisons. *J Periodontol* 1968; 39: 96-100.
6. Broon NJ, Bortoluzzi EA, Bramante CM. Repair of large periapical radiolucent lesions of endodontic origin without surgical treatment. *Aust Endod J* 2007;33: 36-41.
7. Ozan U, Er K. Endodontic treatment of a large cyst-like periradicular lesion using a combination of antibiotic drugs: a case report. *J Endod* 2005;31: 898-900.
8. Oztan M. Endodontic treatment of teeth associated with a large periapical lesion. *Int Endod J* 2002;35: 73-8.
9. Çalışkan M. Prognosis of large cyst-like periapical lesions following nonsurgical root canal treatment: a clinical review. *Int Endod J* 2004;37: 408-16.
10. Eversole LR. *Clinical outline of oral pathology: diagnosis and treatment*: 4<sup>th</sup> ed, PMPH-USA; 2001.

11. Lalonde ER LR. The frequency and distribution of periapical cysts and granulomas. *Oral Surg Oral Med Oral Pathol* 1986;25: 861-8.
12. Bhaskar SN. Periapical lesions- types, incidence, and clinical features. *Oral Surg Oral Med Oral Pathol* 1966;21: 657-71.
13. Ramachandran Nair PNR, Pajarola G, Schroeder HE. Types and incidence of human periapical lesions obtained with extracted teeth. *Oral Surg Oral Med Oral Pathol Oral Radiol Endod* 1996; 81: 93-102.
14. Nair PNR. Apical Periodontitis: a dynamic encounter between root canal infection and host response. *Periodontology* 2000;13: 121-48.
15. Meija JL DJ, Basrani B. Active nonsurgical decompression of large periapical lesions-3 case reports. *J Can Dent Assoc* 2004;70: 691-4.
16. Abbott PV. The periapical space - a dynamic interface. *Aust Endod J* 2002;28: 96-107.
17. Siqueira JF LH. Mechanisms of antimicrobial activity of calcium hydroxide: a critical review. *Int Endod J* 1999;32: 361-9.
18. Sjogren U FS, Spangberg L, Sundqvist G. The antimicrobial effect of calcium hydroxide as a short-term intracanal dressing. *Int Endod J* 1991;24: 119-25.
19. Farhad A, Mohammadi Z. Calcium hydroxide: a review. *Int Dent J* 2005; 55: 293-301.
20. Tronstad L, Andreasen J, Hasselgren G, Kristerson L, Riis I. Ph changes in dental tissues after root canal filling with calcium hydroxide. *J Endod* 1981;7: 17-21.
21. Safavi KE, Nichols FC. Effect of calcium hydroxide on bacterial lipopolysaccharide. *J Endod* 1993;19: 76-8.
22. Seux D, Couble M, Hartmann D, Gauthier J, Magloire H. Odontoblast like cytodifferentiation of human dental pulp cells in vitro in the presence of a calcium hydroxide-containing cement. *Arch Oral Biol* 1991;36: 117-28.
23. Tronstad L AJ, Hasselgren G, Kristerson L, Riis I. pH changes in dental tissue after root canal filling with calcium hydroxide. *J Endod* 1981;7: 17-21.
24. MK. Cak. Prognosis of large cyst-like periapical lesions following nonsurgical root canal treatment: a clinical review. *Int Endod J* 2004;37: 408 -16.
25. Wu MK, van der Sluis LW, Wesselink PR. The capability of two hand instrumentation techniques to

remove the inner layer of dentine in  
oval canals. Int Endod J 2003; 36:

218-24.

**Corresponding author:**

Dr. Saurabh R. Ramtekkar,  
Department of Conservative Dentistry and  
Endodontics, Government Dental College and  
Hospital, Nagpur, India.  
Email ID: ramtekkarsaurabh@gmail.com